

Research Article

Study of aortic calcification in cows examined in Wasit Governorate, Iraq

Asawer Abdul-Jabbar AL-SALMAN¹, Esraa Abdul Khaliq ZEGYER², Hanan Sajjad AL-IEDANI²

¹*Department of Biology, College of Science, University of Wasit, Kut, Iraq.*

²*Department of Pathological Analysis, College of Science, University of Wasit, Kut, Iraq.*

**Email: asawirabi224@uowasit.edu.iq*

Abstract: The aim of this work was to determine the occurrence of calcification in the aortic artery of cows at different ages in Wasit Governorate. The aortic tissue of hearts from healthy cows at the ages of 1, 2, 3 and 4 years was collected. Histological sections from these samples were prepared and stained with Hematoxylin and Eosin and alizarin red, Von Kossa, to determine the deposition of calcium salts. In the 1-year-old group, the wall of the aorta includes the intima, containing one layer of endothelium cells next to the arterial lumen, media with elastic fiber, and adventitia made from connective tissue. Calcium salts at this age had been deposited in tunica media in the form of small white granules. The aortic artery of 2 years group showed the presence of calcium salts as large brown spots in the media layer. Calcification in the aorta of cows at the age of 3 years was larger as large brown clusters. At the age 4 years, calcium salts scattered widely in the middle layer. The results revealed that the calcification increases with the aging animals.

Keywords: Cow, Von Kossa, Aorta, Calcification.

Citation: Al-Salman, A.A.J.; Zegyer, E.A.K. & Al-Iedani, H.S. 2023. Study of aortic calcification in cows in Wasit Governorate, Iraq. Iranian Journal of Ichthyology (Special Issue 1): 14-21.

Introduction

Cow, *Bos taurus*, is a large domestic ungulate (Herzog 2010). Its circulatory system similar to other mammalians, include heart and, blood vessels that transfer blood to peripheral organs and pulmonary vessels to exchange O₂ and CO₂ (Levick 1991; Guyton & Hall 2006). Aorta is the main elastic artery of the cardiovascular system, divided into four parts, viz. ascending, aortic arch, descending thoracic and abdominal aorta (McLaughlin & Chiasson 1987). The aortic wall structure consists of three layers intima, media, and adventitia (Josian et al. 2004).

Calcification is the deposition of calcium salts in an organ that happens naturally in the bones but abnormally (pathologically) deposits into the soft tissues leading to their hardening (Miller 2013). Calcification causes the major pathophysiological alternation of vascular, such as declined vascular contentment and high pulse pressure via increasing

the systolic arterial pressure and reducing the diastolic pressure (Roberts 1986). Calcification of the vascular system is a process controlled by vascular cells and vitamin K-dependent proteins. Vascular calcification comprises calcified plaque of 20-24 μ , causing aortic valve stenosis (Demer & Tintut 2008; Otto 2008; Towler 2008). Calcification of vessels is a pathophysiological disorder accompanying coronary atherosclerosis and also a sign of cardiac sickness leading to death (Raggi et al. 2000; Wilson et al. 2001). This work aimed to study the prevalence of calcium deposits i.e. calcification in the aortic artery of cows at different ages in Wasit Governorate.

Material and methods

A total of 20 healthy cow hearts were collected from a salutory in Wasit Governorate and divided into 4 age groups of 1-4 years; age determination was done using the dental equation (Fig. 1). The aorta was

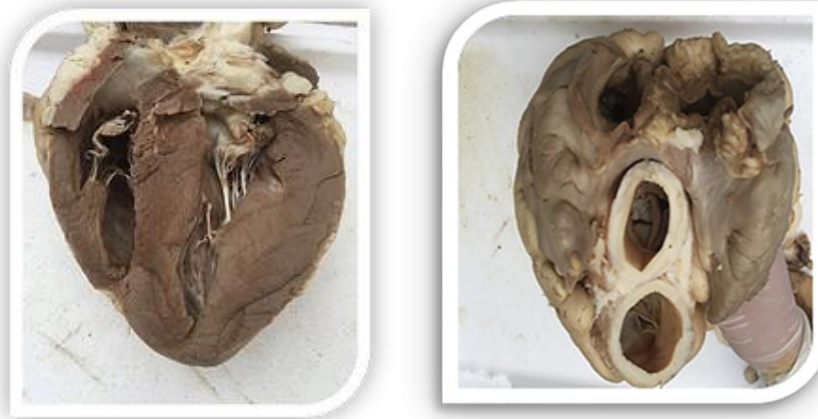

Fig.1. Healthy cow's hearts.

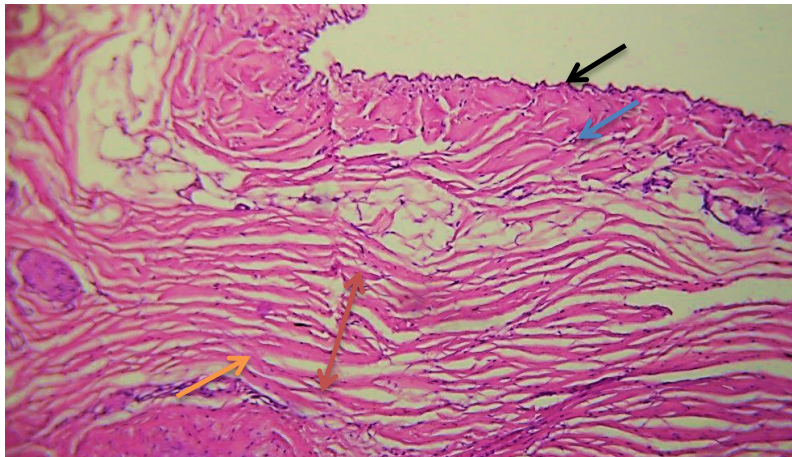


Fig.2. Cross section of aorta of cow at 1 year viewing wall of aorta tunica intima (blue arrow), internal elastic lamina (black arrow), media (red arrow) elastic fiber (orange arrow) (H&E 10X).

examined and removed carefully. Then they were fixed into 10% formalin and, after 48 hours, transferred to 72% alcohol. Then they were processed for histological preparation as follows: dehydrated in ethanol series, cleared in xylene and paraffinization into paraffin wax at 56°C. Afterward, the prepared blocks were cut using an automatic microtome into sections with 5µm thickness; and stained by Hematoxylin and Eosin, Alizarin Red and Von Kossa (Tolosa et al. 2003). The prepared sections were examined under an optical microscope and photographed using a canon digital camera.

Results and Discussion

Aortic calcification in 1-year-old group: The histological observations showed elastic arteries with

walls, including tunica intima, with a layer of endothelium cells next to the arterial lumen. The middle layer consists of elastic fiber, and the last layer is adventitia (outer layer), which form by connective tissue with the diverse thickness (Fig. 2). In the lumen of the aorta, all three layers intima, media, and adventitia contain atherosclerotic plaque, along with the presence of nerves and adipose tissue (Fig. 3). These results agreed with findings of Fletcher et al. (2008) who found the similar structures of the elastic artery. Histological sections of the aortic artery showed calcium deposition in the tunica intima in the form of small white granules (Fig. 4). In the current study, the calcification was observed in the middle layer of the aorta as small brown spots in Von Kossa staining (Fig. 5). Bernacca et al. (1992)

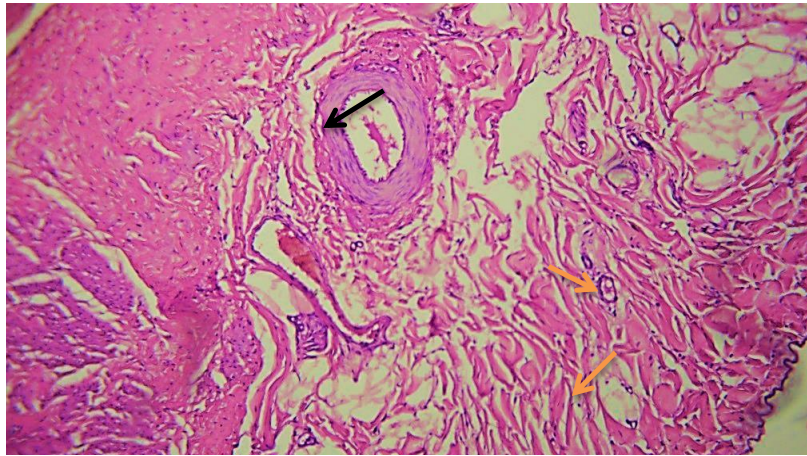


Fig.3. Aorta of cow at 1 year viewing atherosclerotic plaque inside intima (orange arrow), lumen (black arrow) (H& E 10X).

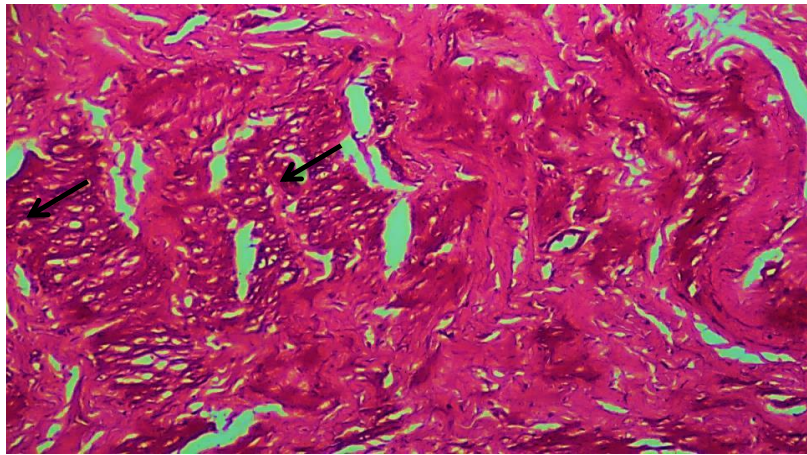


Fig.4. Aorta of cow at 1 year viewing aortic calcification (black arrow) (Alizarin red 20X).

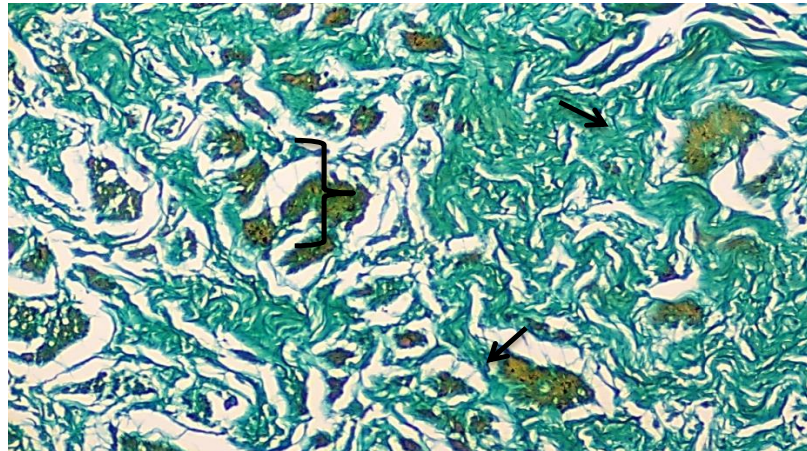


Fig.5. Aorta of cow at 1 year viewing aortic calcification (black arrow) (Von Kossa 20X).

reported focal Ca deposit in bovine valves. Schoen et al. (1999) also showed calcification as small, clearly, foci dispersed in the aorta of sheep.

The results of aortic calcification in two-years-old group: Atherosclerotic plaques were found in the

inner layer (Fig. 6) in the sections stained with alizarin red, which was higher in quantity than 1-year-old group. In the middle layer, the white granules were found in most part of this layer (Fig. 7). This result was in line with Simmons et al. (2005),

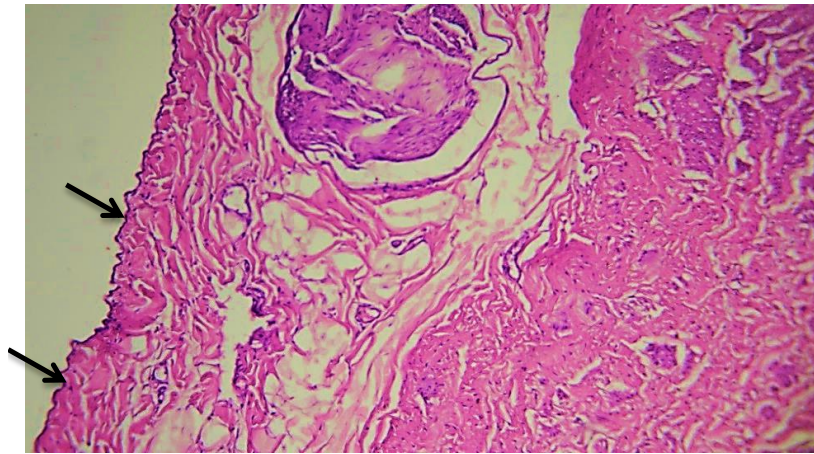


Fig.6. Aorta of cow at 2 years viewing atherosclerotic plaque (black arrow) (H& E 10X).

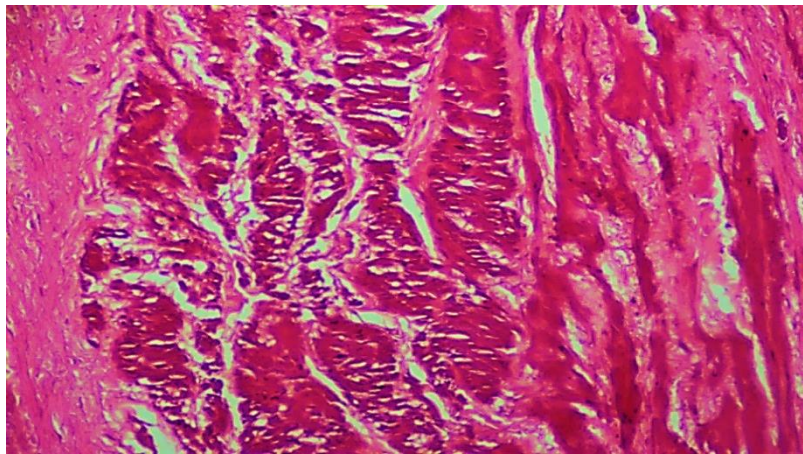


Fig.7. Aorta of cow at 2 years viewing calcification (Alizarin red 20X).

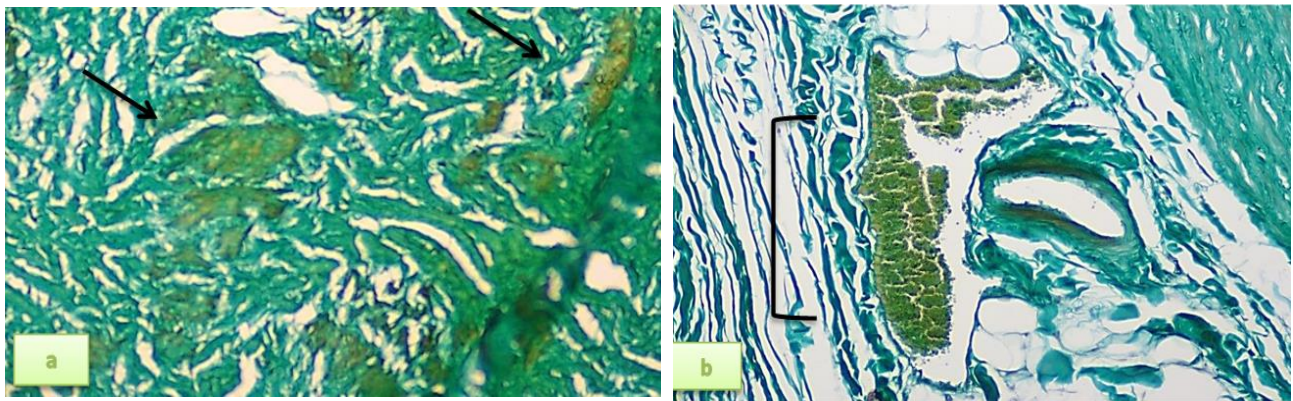


Fig.8. Aorta of cow at 2 years old, black arrow shows aortic calcification, Von Kossa 20X.

who found calcification in pigs aortic by alizarin red stained sections. In stained sections with Von Kossa, large brown spots of calcification were observed in the tunica media (Fig. 8a, b). Schoen & Levy (1999) reported the calcification in the tunica media layer of aortic valve in sheep.

The results of aortic artery at three-years-old group: Adventitial layer was filled with adipose tissue, nerves and large vesicles of vasa vasorum (Fig. 9a, b). In the sections stained with alizarin red, the calcification was greater than in two first age groups (Fig. 10). The calcification in Von Kossa

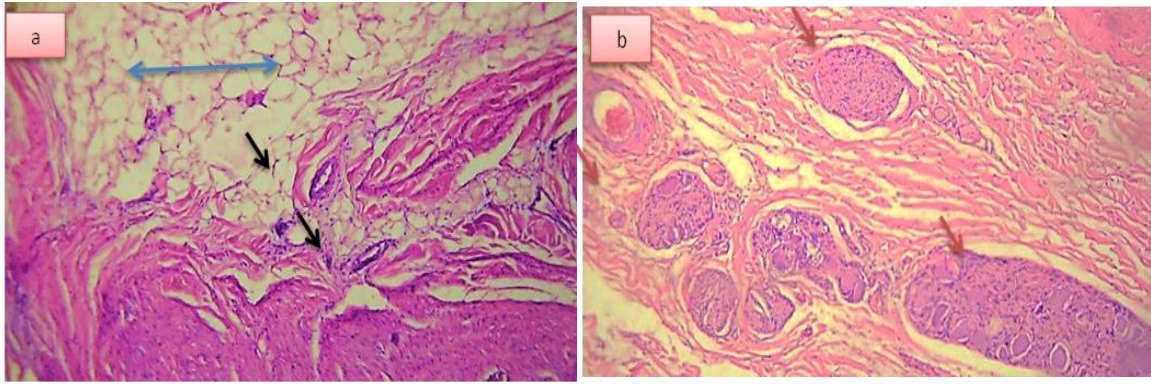


Fig.9. Aorta of cow at 3 years viewing outer layer in which adipose tissue (blue arrow), nerves (black arrow) and vasa vasorum (red arrow) (H&E 10X).

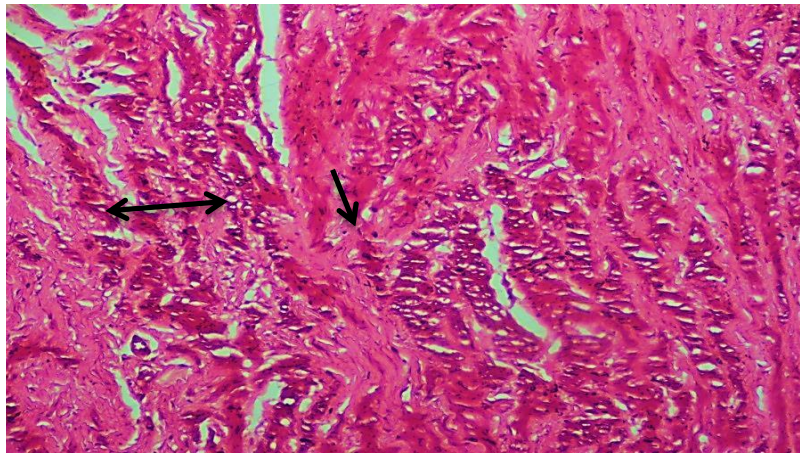


Fig.10. Aorta of cow at 3 years viewing calcification (black arrow) (Alizarin red 20X).

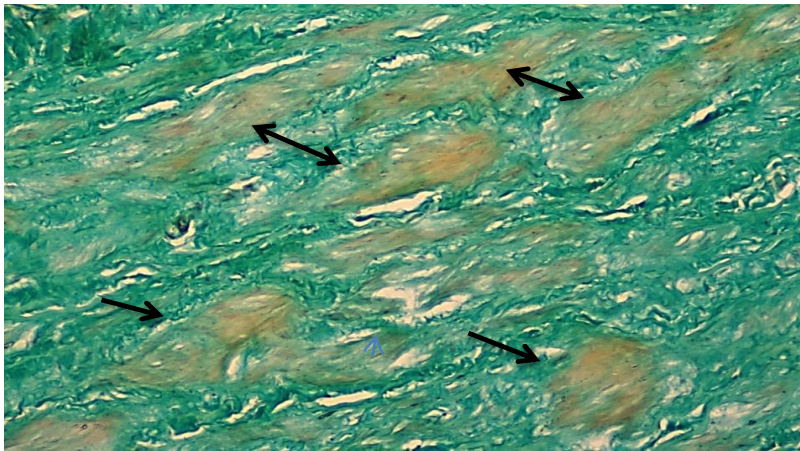


Fig.11. Aorta of cow at 3 years viewing calcification (black arrow) (Von Kossa stain 20X).

stained sections was observed scattered in tunica media as large brown clusters (Fig. 11), larger than two previous groups. This indicates that calcification increases with age in cows as reported by Hofmann et al. (2012) who pointed out increasing of calcium deposition in aorta of adult mice by aging.

The results of aortic artery at four years old: In the 4 year's age group, the outer layer was almost filled with fatty tissue (Fig. 12). Calcium deposition widely occupied the middle layer in the stained sections with alizarin red (Fig. 13). Deposition of calcium salts as large brown areas (Fig. 14), indicates

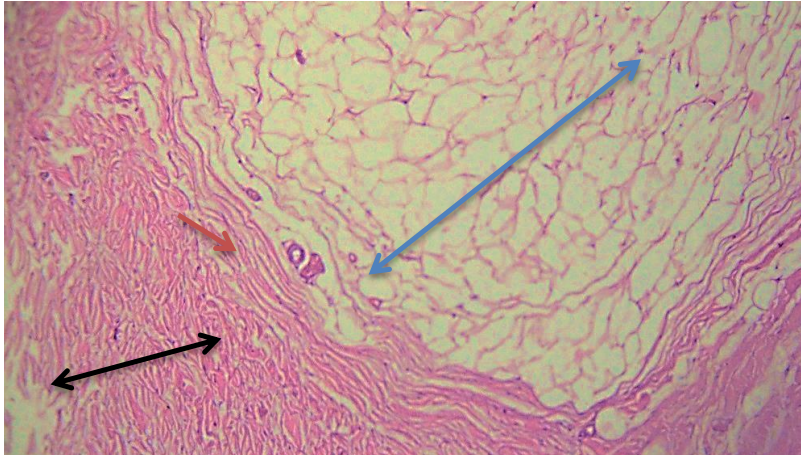


Fig.12. Aorta of cow at 4 years viewing middle and outer layers, tunica media (black arrow), adipose tissue (blue arrow), nerves (red arrow) (H& E 10X).

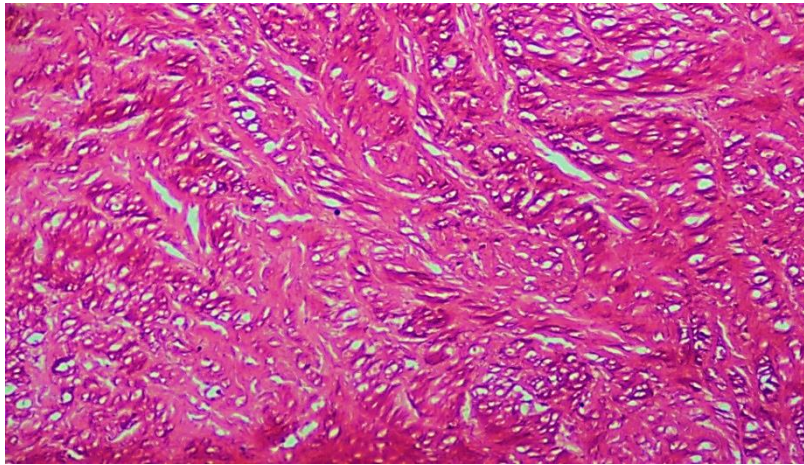


Fig.13. Aorta of cow at 4 years viewing calcification (Alizarin red 20X).



Fig.14. Aorta of cow at 4 years viewing aortic calcification (Von Kossa 20X).

that the calcification increase with the aging of the animal (Fig. 15). The intensity of calcium granules occupied most of three tissue layers. Weiss et al.

(2006) reported the presence of calcification as large bundles scattered throughout the aorta tissues of adult mice.

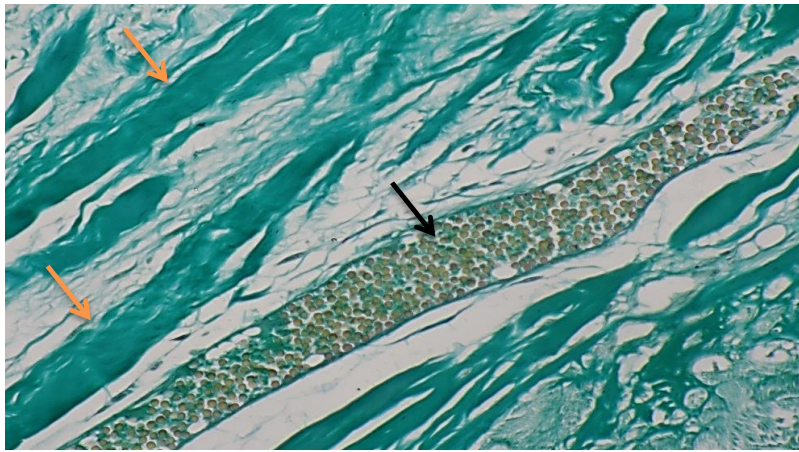


Fig.15. Aorta at aged 4 years viewing calcification (black arrow), elastic fiber (orange arrow) (Von Kossa 40X).

Conclusions

Calcification is an abnormal pathological disorder negatively effects animal health. In the current study, calcification granules were observed in the first and second ages in the form of small granules scattered in the middle layer of the aorta. At the age of 3 years, calcium deposition was higher in the form of brown clusters. These clusters of calcifications were large in the aorta at 4 years of age, revealing that calcification increases with age increase in cows.

Acknowledgments

This research was performed in the laboratories of the Department of Biology, College of Science, University of Wasit.

References

Bernacca G.M.; Fisher, A.C.; Wilkinson, R.; Mackay, T.G. & Wheatley, D.J. 1992. Calcification and stress distribution in bovine pericardial heart valves. *Journal of Biomedical Materials Research* 26: 959-966.

Demer, L.L. & Tintut, Y. 2008. Vascular calcification: pathobiology of a multifaceted disease. *Circulation*. 117: 2938-2948.

Fletcher, O. & Abdul-Aziz, T. 2008. Cardiovascular system. *Avian histopathology*. Madison, USA: American Association of Avian Pathologists, Inc. pp: 98-129.

Guyton, A.C. & Hall, E. 2006. *Textbook of Medical Physiology*. Elsevier Inc. 170 p.

Herzog, H. 2010. Some we love, some we hate, some we

eat: Why it's sohard to think straight about animals. New York, NY: Harper: pp. 237-263.

Hofmann, J.J.; Briot, A.; Enciso, J.; Zovein, A.C.; Ren, S.; Zhang, Z.W.; Radtke, F.; Simons, M.; Wang, Y. & Iruela-Arispe, M.L. 2012. Endothelial deletion of murine Jag1 leads to valve calcification and congenital heart defects associated with Alagille syndrome. *Development* 139: 4449-4460.

Josian, M.M.; Antononio, M.O.; Carlos, R.P.; Selma, M.M. & Maria, L.E. 2004. Structure of the aortic wall in the guinea pig and rat. *Brazilian Journal of Morphological Sciences* 21(1): 35-38.

Levick, J.R. 1991. *An introduction to cardiovascular physiology*, Arnold: pp.1-122.

Miller, J.D. 2013. Cardiovascular calcification: Orbicular origins. *Nature Materials* 12: 476-478.

Otto, C.M. 2008. Calcific aortic stenosis: time to look more closely at the valve. *The New England Journal of Medicine* 359: 1395-1398.

Raggi, P.; Callister, T.Q.; Cooil, B.; He, Z.X.; Lippolis, N.J.; Russo, D.J.; Alan Z. & John J.M. 2000. Identification of patients at increased risk of first unheralded acute myocardial infarction by electron-beam computed tomography. *Circulation* 101(8): 850-855.

Roberts, W.C. 1986. The senile cardiac calcification syndrome. *The American Journal of Cardiology* 58(6): 572-4.

Schoen, F.J.; Hirsch, D.; Bianco, R.W. & Levy, R.J. 1994. Onset and progression of calcification in porcine aortic bioprosthetic valves implanted as orthotopic mitral valve replacements in juvenile sheep. *The Journal of Thoracic and Cardiovascular Surgery* 108: 880-887.

- Schoen, F.J. & Levy, R.J. 1999. Tissue Heart Valves: Current Challenges and Future Research Perspectives. *Journal of Biomedical Materials Research* 47: 439-465.
- Schurgers. J. 2012. Vascular calcification: The price to pay for anticoagulation therapy with vitamin K-antagonists. *Blood Reviews* 26(4): 155-166.
- Simmons, C.A.; Grant, G.R.; Manduchi, E. & Davies, P.F. 2005. Spatial Heterogeneity of Endothelial Phenotypes Correlates With Side Specific Vulnerability to Calcification in Normal Porcine Aortic Valves. *Circulation Research* 96: 792-799.
- Tolosa, E.M.C.; Rodrigues, C.J.; Behemer, A.O. & Freitas-Neto, A.G. 2003. *Manual de Técnicas para Histologia Normal e Patológica*. Manole, São Paulo.
- Towler, D.A. 2008. Vascular calcification: a perspective on an imminent disease epidemic. *IBMS BoneKey* 5: 41-58.
- Weiss, R.M.; Ohashi, M.; Miller, J.D.; Young, S.G. & Heistad, D.D. 2006. Calcific Aortic Valve Stenosis in Old Hypercholesterolemic Mice. *Journal of Circulation* 112: 2065-2069.
- Wilson, P.W.; Kauppila, L.I.; O'Donnell, C.J.; Kiel, D.P.; Hannan, M.; Polak, J.M. & Cupples, L.A. 2001. Abdominal aortic calcific deposits are an important predictor of vascular morbidity and mortality. *Circulation* 103(11): 1529.